

Peanut lectin-binding sites and mucins in benign and malignant colorectal tissues associated with schistosomiasis

M. Lin¹, J. Hanai² and L. Gui¹

¹Department of Pathology, Jinshan Hospital, Shanghai Medical University, Shanghai, China and

²Department of Pathology, Sakai Municipal Hospital, Sakai City, Osaka, Japan

Summary. An immunohistochemical and histochemical comparative study was carried out in benign and malignant colorectal tissues with and without schistosomiasis. This included a quantitative determination of peanut lectin (PNA)-binding sites and proliferating cell nuclear antigen (PCNA) expression and histochemical detection of mucin changes. 133 cases were studied, including 70 cases of colorectal carcinoma associated with schistosomiasis (CCS) and 63 cases of colorectal carcinoma without schistosomiasis (CC). Significant differences were found in the type of mucin-containing carcinomas (MC) between CCS and CC. 65% of non-tumorous mucosa adjacent to MC of the CCS group expressed PNA-binding sites, significantly higher than those of the MC in the CC group (31%). The non-tumorous mucosa in cases of MC of the CCS group also showed a high percentage of sialomucin-predominant secretion (69%, vs 38% in MC of the CC group). Consistently, the presence of PNA-binding sites in MC tumors of the CCS group was increased, compared with that in the same subtype in the CC group (respectively 65% and 31% of strong positivity for PNA). However, no differences in expression of PNA and mucin changes were demonstrated in the surrounding mucosa and tumorous tissues of non-mucin-containing carcinomas (NMC) between CCS and CC. The expression of PCNA was not different between CCS and CC and their subtypes. Our findings suggest a close relationship between mucin-containing colorectal carcinomas and schistosomiasis japonica.

Key words: Colorectal cancer, mucin-containing type, schistosomiasis, PNA-binding site, PCNA, sialomucins and sulphomucins

Introduction

In east Asia an important and serious schistosome infection, i.e., *S. japonicum*, was and is present, influencing the population in China, the Philippines, Indonesia and Japan. Colonic schistosomiasis has been one of the most common diseases in these areas, which are frequently associated with colorectal cancer. The high prevalence of colorectal cancer in these areas endemic for schistosomiasis (Zhang, 1985; Li, 1988), and some characteristic clinical findings and morphological changes in colorectal cancer associated with schistosomiasis (Chen et al., 1965, 1980, 1981; Chuang et al., 1979; Zhao and Wong, 1981; Naito et al., 1982) led investigators to postulate a causal association between schistosomiasis and colorectal cancer in these countries. However, in spite of a certain amount of studies from various fields, the association of schistosomiasis and cancer is hard to be clearly established and our knowledge of the causal connection has not been convincingly obtained (Dimmette et al., 1956; Xuan, 1982; Zhang, 1985). In previous studies we found a high incidence of mucinous carcinoma in colorectal cancer associated with schistosomiasis (CCS), which was related to the amount of ova deposition (Tokoro and Koganezawa, 1977; Lin et al., 1993; Lin, 1994). For further study, we have evaluated peanut lectin (PNA) binding for specific sugar and analyzed mucin properties in tumorous and non-tumorous tissues of the cases of colorectal carcinomas associated with schistosomiasis japonica. The specific disaccharides and altered mucin composition were proved to be possibly useful indicators of early malignant transformation of colonic epithelia (Klein et al., 1981; Cooper, 1982; Greaves et al., 1984; Yang and Shamsuddin, 1996). The tumors with and without obvious mucinous carcinoma elements were separately studied, and compared with those of colorectal carcinomas without schistosomiasis (CC).

Materials and methods

Between 1988-1993 there were 133 cases of surgical specimens of colorectal cancer in Jinshan Hospital, the slides and paraffin blocks of which were retrieved and studied. Among them, 70 cases were the CCS group, showing deposition of ova in the tumour and surrounding tissue, and 63 cases having no ova constituted the CC group. The two groups were subdivided into mucin-containing (MC) and non-mucin-containing (NMC) subtypes, i.e., carcinomas which contained more than 20% of mucinous carcinoma element were MC; and the others, NMC. The tumorous tissues and non-tumorous mucosa adjacent to the tumor was also studied.

The blocks were cut into 5 μ m-thick serial sections and were used for PNA (peanut agglutinin), PCNA (proliferating cell nuclear antigen) immunostaining and HID-AB mucin staining.

Sections for immunostainings were deparaffinized, rehydrated and immersed for 5 min in phosphate-buffered saline with 3% hydrogen peroxide to block endogenous peroxidase. For each case the first section was incubated with biotinylated peanut agglutinin (Vector Laboratories, USA), and the second section incubated for 20 min in normal horse serum, then in PCNA primary monoclonal antibody (DAKO, USA) for 1 h, followed by a 1 h incubation of biotinylated antimouse immunoglobulins. Subsequently the two sections were incubated with ABC complex for 1 h. Diaminobenzidine-hydrogen peroxide was employed as a chromogen and a light 0.5 Harris' hematoxylin counterstain was applied. As an immunostaining negative control in counterpart sections lectin and PCNA primary antibody were replaced by phosphate-buffered saline.

Quantitative evaluation of the presence and proportion of PNA-binding sites was made. Over 25% of cells showing PNA binding were defined as strongly positive (++); 25-50% cells expressing PNA were regarded as positive(+), and less than 5%, weakly positive(\pm).

HID-AB (High iron-diamine-alcian blue) mucin staining with AB staining at pH 2.5 was performed. Sulphomucins reacting with diamines give a brown-black colour, whereas sialomucins reacting with Alcian blue are coloured blue. On this staining, a predominance of sialomucins (50% or more) is regarded as "abnormal mucin pattern" (Greaves et al, 1984).

To evaluate the expression of PCNA in the tissues, an absolute count of PCNA immunoreactivity was performed by observing random high power fields and scoring a minimum of 2000 cells, and the expression of PCNA by tumor cells and non-tumor tissues was recorded separately. Furthermore, because of the different distribution of PCNA, non-tumor tissues were separately observed at their basal layer, middle layer and superficial layer. The cellular proliferative index was expressed as the percentage of positivity of PCNA.

All results were compared between CCS and CC,

and Student's t-test and χ^2 -test were used for statistical analysis.

Results

The table shows that the percentages of MC and NMC subtypes in CCS and CC are significantly different; MC in CCS is 37%, higher than 21% in CC.

1. PNA-binding sites in tumorous and non-tumorous tissues of CCS and CC and their subtypes

From the table it can be seen that the tumorous and non-tumorous tissues of both CCS and CC groups possessed positive cases of PNA staining. However, tumors of the CCS group exhibited a much higher percentage of strongly positive cases, significantly in the MC subtype (65%) (Fig. 1). Consistently, in non-tumorous mucosa the CCS group showed 47% of positive cases, significantly higher than those of the CC group. The difference was mainly found in MC subtype of CCS: 65% MC of the CCS group exhibited PNA binding, and in MC of the CC group, only 31%. Although in the CCS group some cases only expressed apical localization of PNA (Fig. 2), cytoplasmic positivity could also be often observed (Fig. 3). In some cases, PNA-binding sites were observed in quite a large region of the schistosomal mucosa.

2. Mucin changes in CCS and CC and their surrounding tissues

Mucins produced by tumor cells was variable in CCS and CC, and no difference were found between the two groups and their subtypes. Sialomucins were often found in tumor tissue, but some tumors exhibited no mucin at all. However, non-tumorous mucosa of the CCS group showed a 54% increase in sialomucin

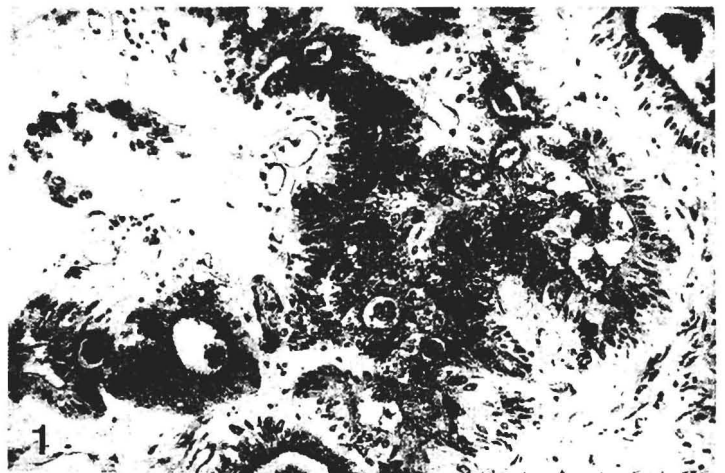


Fig. 1. Strong PNA staining in a mucinous carcinoma associated with schistosomiasis. ABC method. x 330

secretion, higher than the 40% in CC cases. The significant difference in mucin composition was present in the non-tumorous mucosa of MC subtype between CCS and CC; and in MC of CCS cases predominance of sialomucins was 69%, contrasting sharply with 38% in MC of CC cases (Table 1).

3. Expression of PCNA in tumorous and non-tumorous tissues of CCS and CC and their subtypes

The results showed that there was no significant difference in PCNA immunoreactivity between CCS and CC (including tumorous and non-tumorous tissues). The average PCNA indices in CCS and CC were 67.2% and

68.3%, respectively. In non-tumorous mucosa of both groups PCNA positivity was occasionally observed in the superficial layer, and the basal layer showed the highest index among three layers, but the latter was lower than that of tumor tissues.

Discussion

Our and other previous studies have demonstrated a high percentage of mucinous carcinomas in CCS (Department of Pathology, Suchou Medical College, 1977; Zhao and Wong, 1981). This further study used immunohistochemical and histochemical methods which have often been applied to studying colorectal cancer but

Table 1. PNA-binding sites and mucin changes in benign and malignant tissues of CCS and CC and their subtypes.

SUBTYPE	CCS		CC		MC				NMC			
					CCS		CC		CCS		CC	
No.	70		63		26	37%	13	21%**	44	63%	50	79%**
<i>In tumor tissue</i>												
PNA ++	27	39%	16	25%	17	65%	4	31%**	10	22%	12	24%
PNA +	35	50%	39	62%	9	35%	9	69%	26	59%	30	60%
PNA -	8	11%	8	13%	0		0		8	18%	8	16%
P.Sulphom.	20	29%	19	30%	4	15%	4	31%	16	36%	15	30%
P.Sialom.	34	49%	28	44%	22	85%	9	69%	12	27%	19	38%
No mucin	16	22%	16	25%	0		0		16	36%	16	32%
<i>In non-tumor tissues</i>												
PNA +	33	47%	16	25%***	17	65%	4	31%**	16	36%	12	24%
PNA -	37	53%	47	75%***	9	35%	9	69%**	28	64%	38	76%
P.Sulphom.	32	46%	38	60%	8	31%	8	62%*	24	55%	30	60%
P.Sialom.	38	54%	25	40%	18	69%	5	38%*	20	45%	20	40%

By Student's t-test between CCS and CC, ***: $0.001 < p < 0.01$; **: $0.01 < p < 0.05$; *: $p = 0.05$. CCS: colorectal carcinoma with schistosomiasis; CC: colorectal carcinoma without schistosomiasis; MC: carcinoma containing 20% or more mucinous element; NMC: carcinoma containing no more than 20% of mucinous elements; P.Sulphom.: predominance of sulphomucins; P.Sialom.: predominance of sialomucins.

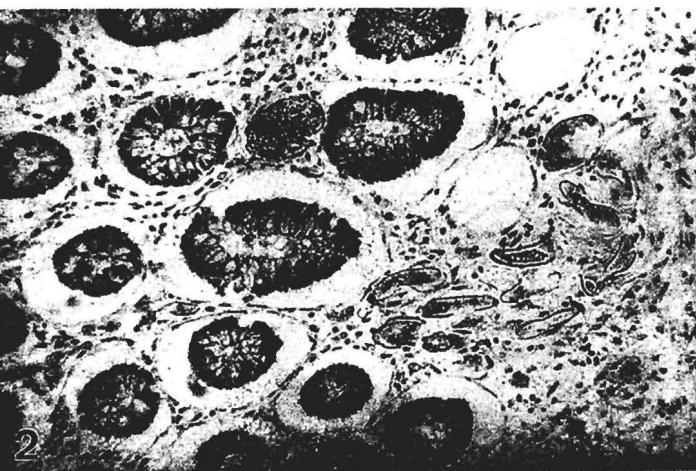

Fig. 2. Apical localization of PNA in the normal glands of schistosomal mucosa with heavy deposition of ova. ABC method. x 330

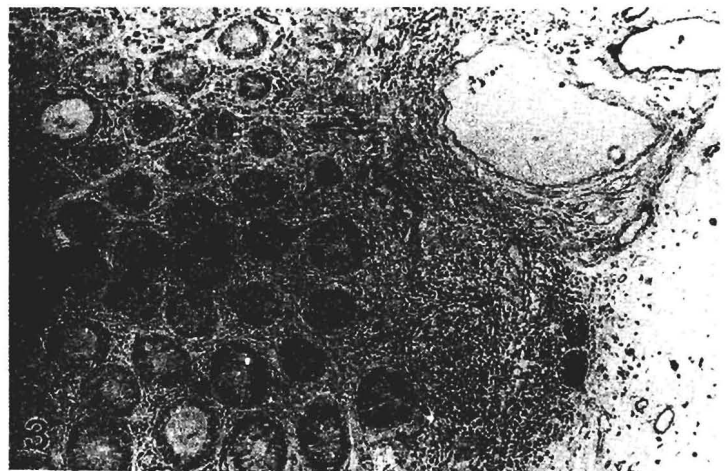


Fig. 3. Cytoplasmic positivity of PNA in the normal mucosa with deposition of schistosomal ova and chronic inflammation. ABC method. x 160

have not been recorded in CCS.

In this study the results showed a significantly higher expression of PNA binding in the tumorous tissue and benign mucosa of MC cases in the CCS group. PNA has an ability to bind to specific sugar molecules that have been proved to relate to early malignant change (Klein et al., 1981; Boland et al., 1982; Cooper, 1982, 1984; Yuan et al., 1986), and recently PNA has been believed to be a biomarker of colon carcinogenesis (Yang and Shamsuddin, 1996). Therefore, the high frequency of PNA-binding sites in non-tumorous tissues of the CCS group and its MC subtype could be regarded as a malignant transformation of the epithelia, and might be connected with schistosomiasis. If these malignant changes in the schistosomal colon were postulated to result in MC subtype tumors, it could explain the significantly high proportion of MC in the CCS group.

Furthermore, mucin alternation in schistosomal colon revealed in this study provided another evidence for the above postulation. Our results show that in MC of the CCS cases the non-tumorous mucosa increased sialomucin-secretion and showed a higher percentage of predominance of sialomucins than that in the MC cases of CC. Some authors believe that an increase of sialomucins is a sensitive indicator of early malignant change (Filipe and Branfoot, 1976; Greaves et al., 1984; Allen and Hoskins, 1987). The mucin alterations have been assessed for their value in identifying early development of epithelial dysplasia and premalignant changes in chronic ulcerative colitis (Ehsanullah et al., 1985), and these alterations should have the same meaning in schistosomal colon. By comparison of mucin patterns in CC and CCS, our study proved that there was also a high dysplasia tendency in the schistosomal colonic mucosa and that it was closely related to the tumors containing mucinous carcinoma element. This finding is concordant with the results of PNA expression.

In PCNA immunostaining the results showed no difference between CCS and CC, or in either MC or NMC subtypes. Although there remain doubts concerning the significance of PCNA expression and its relation to cell proliferation (Hall et al., 1990), PCNA is more highly expressed in tissues with active proliferation. This could also be seen in the present study. The distribution of PCNA staining was generally high in tumor tissues, and in normal tissues the basal layer, the most actively proliferative area, showed the highest PCNA index.

Some authors found no significant increase of adenomatous polyps and anaplastic polyps in the colorectum of *S. japonicum* infection group (Dimmette et al., 1956; Xuan, 1982; Zhang, 1985; Zheng et al., 1991). In relation to these findings and our PCNA immunostaining results, it seems that cellular proliferation does not increase in the schistosomal colon and rectum. Because of the low incidence of adenomatous polyps and anaplastic polyps in the schistosomal colon, the researchers concluded that "No relationship between schistosomiasis and colorectal cancer was found".

However, we have wondered whether low incidence of polyps can deny the relationship between schistosomiasis and colorectal cancer, and whether the evidence about the carcinogenesis of schistosomiasis should lay emphasis on polyps only. Some authors believe that the sequence of colorectal cancerous change should be as follows: "normal intestinal epithelium → tumorigenic polyp or colorectal ulcer → polyp with anaplastic change → polyp with local cancerous change → adenocarcinoma" (Zhang, 1985), whereas we think that although a certain amount of colorectal carcinomas originate from adenomas, a large amount of the tumors might be produced directly from the foci of epithelial dysplasia in flat mucosa (Lemmer and Fripp, 1994). Considering the epidemiologically close relationship between schistosomiasis and colorectal cancer (Xu and Su, 1984; Guo, 1987; Li, 1988; Guo et al., 1993), and distinctive characters of CCS with age, tumor distribution, histological findings and classification (Wu et al., 1960; Shindo, 1976; Chuang et al., 1979; Zhao and Wong, 1981; Naito et al., 1982; Lin et al., 1993), as well as the results in the present study, we cannot deny a positive correlation between schistosomiasis and colorectal cancer, even no special finding in PCNA immunostaining. Our studies suggest a high possibility that not all CCS result from schistosomiasis but the MC types of CCS are positively related to schistosomiasis and its egg load. This postulation could explain the high incidence of mucinous carcinoma in CCS, and the distinctive immunohistochemical and histochemical characteristics in MC of CCS.

In pathological analysis of carcinoma associated with chronic ulcerative colitis, it was found that the latter possessed a higher proportion of colloid (i.e. mucinous) carcinoma, and over half of the younger patients had mucin-secreting tumors (Stahl et al., 1981). These findings were rather similar to those found in CCS. These similarities suggest that they have resembling pathogenesis, and *S. japonicum* might cause a tumor partly in one possible way-chronic inflammation.

However, development of a tumour should not be considered in a simple way, and many causes might join together in the formation a tumor. In the case of CCS, the parasite egg load, damage of the mucosa, naturally occurring carcinogens, dietary factors and cultural or behavioral patterns cannot all be dismissed. Amano (1980) has suggested that schistosomal eggs might act as a promoting factor in the formation of intestinal tumors. Moreover, a series of experimental studies showed that schistosome infection produced accelerated cancer formation in animals (Ishii et al., 1994), and by molecular techniques possible factors of carcinogenesis have been demonstrated in the *S. japonicum* eggs (Iwamura et al., 1991). In the analysis of 430 cases of CCS, a 5-year survival rate of CCS was 45.6%, lower than that of CC, and was associated with a higher percentage of negative immune response in the regional lymph nodes and higher percentage of infiltrating growth pattern (National Cooperative Group on

Pathology and Prognosis of Colorectal Cancer, 1986). Therefore, about schistosomiasis and its relation to cancer a further wide-range study is necessary.

In conclusion, it can be proposed that schistosomiasis has a causal relation with certain types of colorectal cancer. The latter might be produced directly from the diseased mucosa, or more often from carcinomas of mucinous type.

References

- Allen A. and Hoskins L.C. (1987). Colonic mucus in health and disease. In: Diseases of the colon, rectum, and anal canal. Springer-Verlag. Berlin. Heidelberg. New York. pp 65-94.
- Amano T. (1980). Clinicopathological studies of the gastrointestinal schistosomiasis in the endemic area of Yamanashi prefecture, with special reference to the carcinogenicity of schistosome infection. Jpn. J. Parasitol. 29, 305-312 (in Japanese).
- Boland C.R., Montgomery C.K. and Kim Y.S. (1982). Alterations in human colonic mucin occurring with cellular differentiation and malignant transformation. Proc. Natl. Acad. Sci. USA 79, 2051-2055.
- Chen M.C., Hu R.J., Zhan P.Y., Chuang C.Y., Chao P.F., Chang S.H., Wang F.P., Chen T.L. and Chou S.C. (1965). Pathogenesis of carcinoma of the colon and rectum in schistosomiasis japonica. Chinese Med. J. Engl. 84, 513-525.
- Chen M.C., Chang C.Y., Zhan P.Y. and Hu R.J. (1980). Evolution of colorectal cancer in schistosomiasis: transitional mucosal changes adjacent to large intestinal carcinoma in colectomy specimens. Cancer 46, 1661-1675.
- Chen M.C., Chang C.Y., Chen Y.J., Wang J.P., Tang Y.C. and Chou S.C. (1981). Colorectal cancer and schistosomiasis. Lancet 971-973.
- Chuang C.Y., Chang P.Y., Hu J.C. and Chen M.C. (1979). Pathomorphologic observations on the relations between late schistosomiasis colitis and colorectal cancer. Chinese Med. J. 92, 113-118.
- Cooper H.S. (1982). Peanut lectin-binding sites in large bowel carcinoma. Lab. Invest. 47, 383-390.
- Cooper H.S. (1984). Lectin as probes in histochemistry: the peanut (*Arachis hypogaea*) lectin. Hum. Pathol. 15, 904-906.
- Department of Pathology, Suchou Medical College (1977). Late schistosomiasis colitis and pathomorphologic observation of the cancerization change. Chun Hua Hei Ko Tsa Chih 5, 282-284 (in Chinese).
- Dimmette R.M., Elwi A.M. and Sproat H.F. (1956). Relationship of schistosomiasis to polyposis and adenocarcinoma of large intestine. Am. J. Clin. Pathol. 26, 266-276.
- Ehsanullah M., Morgan M.N., Filipe M.I. and Gazzard B. (1985). Sialomucins in the assessment of dysplasia and cancer risk in patients with ulcerative colitis treated with colectomy and ileorectal anastomosis. Histopathology 9, 223-235.
- Filipe M.I. and Branfoot A.C. (1976). Mucin histochemistry of the colon. In: Pathology of the gastro-intestinal tract. Morson B.C. (ed). Springer-Verlag. Berlin, Heidelberg, New York. pp 143-178.
- Greaves P., Filipe M.I., Abbas S. and Ormerod M.G. (1984). Sialomucins and carcinoembryonic antigen in the evolution of colorectal cancer. Histopathology 8, 825-834.
- Guo Z.R. (1987). Schistosomiasis japonicum and colon cancer - an injury about the pathogenesis of colon cancer by using the logistic regression model. Chung hua Liu Hsing Ping Hsueh Tsa Chih 8, 21-24 (in Chinese).
- Guo W., Zheng W., Li J.Y., Chen J.S. and Blot W.J. (1993). Correlations of colon cancer mortality with dietary factors, serum markers, and schistosomiasis in China. Nutr. Cancer 20, 13-20.
- Hall P.A., Levison D.A., Woods A.L., Yu C.C., Kellock D.B., Watkins J.A., Barnes D.M., Gillet C.E., Camplejohn R., Dover R., Waseem N.H. and Lane D.P. (1990). Proliferating cell nuclear antigen (PCNA) immunolocalization in paraffin sections: an index of cell proliferation with evidence of deregulated expression in some neoplasms. J. Pathol. 162, 285-294.
- Ishii A., Matsuoka H., Aji T., Ohta N., Arimoto S., Wataya Y. and Hayatsu H. (1994). Parasite infection and cancer: with special emphasis on *Schistosoma japonicum* infections. Mutat. Res. 305, 273-281.
- Iwamura Y., Irie Y., Kominami R., Nara T. and Yasuraoka K. (1991). Existence of host-related DNA sequences in the schistosome genome. Parasitology 102, 397-403.
- Klein P.J., Osmer R., Vierbuchen M., Ortmann M., Kania J. and Uhlenbruck G. (1981). The importance of lectin binding sites and carcinoembryonic antigen with regard to normal, hyperplastic, adenomatous and carcinomatous colonic mucosa. Recent Results Cancer Res. 79, 1-9.
- Lemmer L.B. and Fripp P.J. (1994). Schistosomiasis and malignancy. S. Afr. Med. J. 84, 211-215.
- Li Y. (1988). Geographical correlation analysis between schistosomiasis and large intestine cancer. Chung Hua Liu Hsing Ping Hsueh Tsa Chih 9, 265-268 (in Chinese).
- Lin M.S. (1994). Histopathologic subtypes of colorectal carcinoma with and without schistosomiasis and its relationship to ova deposition - an analysis of 147 cases. Tumor (Shanghai) 15, 332-333 (in Chinese).
- Lin M.S., Hanai J. and Sakurai M. (1993). Colorectal carcinoma with schistosomiasis - a clinically and histologically comparative study of 147 cases. T. Soc. Pathol. Jpn. 82, 305.
- Naito H., Hishida H., Tomokiyo A., Mano M., Ueki T., Miyoshi A., Tomoda S., Nakayama N. and Kanyo S. (1982). Clinico-pathological study of colorectal carcinoma with schistosomiasis Japonica - a study of 29 cases. Jpn. J. Cancer Clin. 28, 315-320 (in Japanese).
- National Cooperative Group on Pathology and Prognosis of Colorectal Cancer (1986). Schistosomiasis and its prognostic significance in patients with colorectal cancer. Chung Hua Chung Liu Tsa Chih 8, 149-151 (in Chinese).
- Shindo K. (1976). Significance of *Schistosomiasis japonica* in the development of cancer of the large intestine: report of a case and review of the literature. Dis. Colon Rectum 19, 460-469.
- Stahl D., Tyler G. and Fischer J.E. (1981). Inflammatory bowel disease - relationship to carcinoma. Curr. Prob. Cancer 5, 3-72.
- Tokoro Y. and Koganezawa S. (1977). Metrical and Histopathological studies on 2 cases of Japanese schistosomiasis displaying tremendous numbers of eggs combined with colon cancers. Nippon Shokakibyo Gakkai Zasshi 73, 972-985 (in Japanese).
- Wu Z.D., Chen D.H. and Zhu Q. (1960). The relationship of schistosomiasis to carcinoma of large intestine. Chinese Med. J. Engl. 80, 231-242.
- Xu Z. and Su D.L. (1984). *Schistosoma japonicum* and colorectal cancer: an epidemiological study in the People's Republic China. Int. J. Cancer 34, 315-318.

- Xuan X.L. (1982). An investigation of the correlation between schistosomiasis and colon cancer. *Chung Hua Nei Ko Tsa Chih* 21, 416-418 (in Chinese).
- Yang G.Y. and Shamsuddin M. (1996). Gal-GalNAc is a biomaker of colon carcinogenesis. *Histol Histopathol* 11, 801-806.
- Yuan M., Steven H., Itzkowitz C., Boland R., Kim Y.D., Tomita J.T., Palekar A., Bennington J.L., Trump B.F. and Kim Y.S. (1986). Comparison of T-antigen expression in normal, premalignant and malignant human colonic tissue using lectin and antibody immuno-histochemistry. *Cancer Res.* 46, 4848-4852.
- Zhao E.S. and Wong Y.H. (1981). Carcinoma of the large intestine with schistosomiasis-analysis of 279 cases. *Chung Hua Chung Liu Tsa Chih* 3, 67-69 (in Chinese).
- Zhang S.Q. (1985). Screening and prevention of colorectal cancer in Haining County. *Dis. Colon Rectum* 28, 300-304.
- Zheng G.M., Choi B.C., Yu X.R., Zou R.B., Shao Y.W and Ma X.Y. (1991). Mass screening for rectal neoplasm in Jiashan County, China. *J. Clin. Epidemiol.* 44, 1379-1385.

Accepted March 3, 1998